

# Perigraft infections due to *Salmonella* after abdominal aortic aneurysm repair

Viswanathan R, Khee T K, Chong C F

## ABSTRACT

**A 70-year-old man with abdominal aortic aneurysm repair presented with fever accompanied by rigors and abdominal pain one month after the procedure. Radiological investigations showed a perigraft collection. The collection was drained and the abscess cavity was lavaged. Cultures of pus and blood both yielded Group D *Salmonella* (non-typhi), which was treated with ceftriaxone and ciprofloxacin. The patient was followed-up for the past eight months without any further symptoms. Perigraft infections post abdominal aortic aneurysm repair could be caused by enteric organisms and must be treated with long-term appropriate antibiotics, depending on the microbiological finding, besides surgical drainage and lavage.**

**Keywords:** abdominal aortic aneurysm repair, aneurysm graft infection, perigraft repair, *Salmonella* spp, salmonellosis

*Singapore Med J* 2008;49(7):e183-e185

## INTRODUCTION

Infected abdominal aortic aneurysms (AAA) due to *Salmonella* are common.<sup>(1,2)</sup> However, abdominal aortic graft infections due to *Salmonella* are rare. Conventional management of infected abdominal aortic graft involves explantation of the infected graft with *in situ* autologous superficial femoropopliteal vein graft replacement or creation of an extra-anatomical bypass.<sup>(3,4)</sup> We report an unusual case, where *Salmonella* has been implicated in perigraft infection, which was successfully treated with conservative approach of surgical drainage of perigraft collection and lavage of the cavity with long-term antibiotic therapy.

## CASE REPORT

A 70-year-old male non-smoker with a 3.8 cm infra-renal AAA diagnosed in 1998 was followed-up in the surgical clinic every six months for the past eight years. During this time, the AAA gradually increased in size

with no acute symptoms until October 2006, when he was admitted with severe abdominal pain radiating to the left side. Computed tomography (CT) showed that the AAA has increased in size to 4.5 cm. Because of his acute presentation, he underwent an emergency repair using a 22-mm straight Gortex graft. Part of the excised aneurysm was sent for histopathological and microbiological studies. The histopathology showed an atherosclerotic vessel wall, and the culture grew *Aeromonas sobria* sensitive to ampicillin, amoxicillin and clavulanic acid, cefoperazone, ceftazidime, cefuroxime, cephalixin, chloramphenicol, gentamycin, imipenem and netilmicin. The patient was given three doses of cefuroxime and was then changed to ceftazidime for two weeks. The patient had uneventful postoperative recovery and was discharged home after 14 days.

One month later, he came back with a history of fever with rigors and abdominal pain of two weeks' duration. He admitted to having an episode of gastroenteritis from food poisoning a few days prior to the onset of fever and rigor. Ultrasonography done at that time showed a patent graft with a perigraft collection. CT showed a non-enhancing collection around the graft in the aortic sheath extending to the aortic bifurcation (Fig. 1a). There was no evidence of leakage. Emergency laparotomy was performed and the periaortic graft collection was drained. The graft was fully epithelialised with dense surrounding adhesions, making exposure of the entire graft difficult. Hence, a decision was made to preserve the graft and continue with intravenous antibiotics and perigraft lavage via two 12Fr Redivac drains in the abscess cavity.

Culture of the pus yielded Group D non-typhi *Salmonella*. Blood cultures taken on admission also grew the same *Salmonella* sensitive to ceftazidime, ampicillin, ceftriaxone, cefuroxime, cefoperazone, ciprofloxacin, amoxicillin and clavulanic acid.

The patient was then treated with ceftriaxone and ciprofloxacin for one month. The perigraft cavity was lavaged daily with povidone-iodone for one month, after which the Redivac drains were removed. Antibiotics

Department of  
Laboratory Services,  
RIPAS Hospital,  
Ministry Of Health,  
Bandar Seri  
Begawan,  
BA 1710,  
Brunei Darussalam

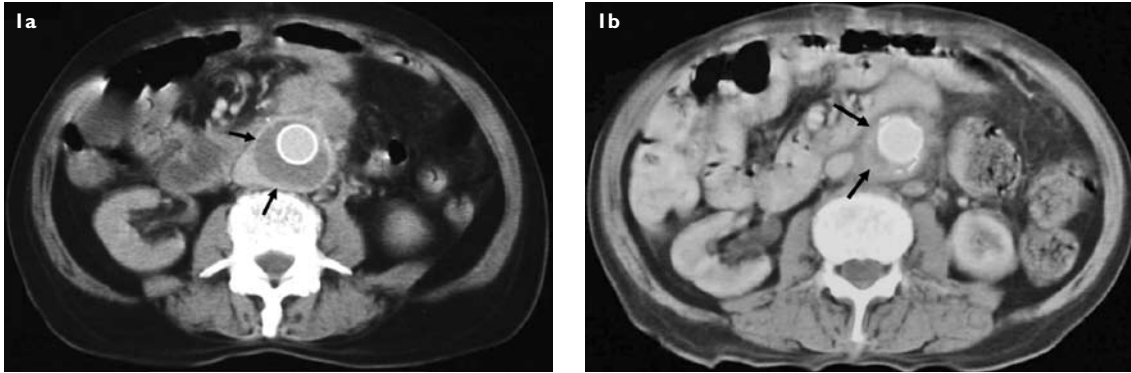
Viswanathan R,  
MBBS, MD  
Clinical  
Microbiologist and  
Infection Control  
Officer

Department of  
Surgical Services

Khee TK, MBCh,  
FRCS  
Specialist

Chong CF, MBBS,  
FRCS, FRCS  
Specialist

Correspondence to:  
Dr Roopa  
Viswanathan  
Tel: (673) 8163 344  
Fax: (673) 2220 869  
Email: ruvishy@  
rediffmail.com



**Fig. 1** Contrast-enhanced axial CT images show (a) the perigraft collection (black arrows) around the infected abdominal aortic graft; and (b) resolution of the perigraft collection (black arrows) four months after surgical drainage with cavity lavage and long-term antibiotics cover.

were stopped as he developed an allergic rash all over his body. He was then given an amoxicillin and clavulanic acid combination for 4 months, by which time his inflammatory markers, C-reactive protein and erythrocyte sedimentation rate were normalised. The patient was reviewed regularly every three months for the past eight months since the antibiotics were stopped, and he remained well with no fever or rigor. His latest CT scan performed in February 2007 showed that the abscess cavity has completely resolved and obliterated (Fig. 1b).

## DISCUSSION

The incidence of non-typhi *Salmonella* infections of native AAA is fairly common and ranges from 50%–70%.<sup>(1,2)</sup> However, abdominal aortic graft infections due to *Salmonella* are rare. The most common organisms associated with abdominal aortic graft infections are *Staphylococcus epidermidis* and *Streptococcus faecalis*.<sup>(4)</sup> The most likely cause of our patient's abdominal aortic graft infection was from haematogeneous seeding from an episode of food poisoning. Latent *Salmonella* infection in the aneurysm wall was ruled out, as the organism was not isolated in the original cultures taken at the time of first surgical excision. Furthermore, the patient admitted to having an episode of gastroenteritis due to food poisoning a few days prior to the onset of fever and rigors.

Management of the infected abdominal aortic graft poses a difficult surgical problem and conventionally involves explantation of the infected graft with *in situ* graft replacement or extra-anatomical bypass.<sup>(1,3-5)</sup> Graft replacement using autologous superficial femoropopliteal vein has been well reported with a good success rate in treating aortic graft infection.<sup>(3)</sup> Extra-anatomical bypass such as axillo-femoral or axillo-iliac bypass is another alternative solution to managing infected abdominal aortic graft.<sup>(1,5)</sup> However, both these surgical

techniques carry significant high mortality and are also associated with long-term complications, such as stricture formation at anastomotic sites with autologous superficial femoropopliteal bypass or graft occlusions and infections with extra-anatomical bypass.<sup>(3,6)</sup>

There are a few reports in cases where the operative mortality was high; conservative management using percutaneous or surgical drainage of the perigraft collection, followed by perigraft lavage and antibiotics, have been successful in treating abdominal aortic graft infection.<sup>(7,8)</sup> In our case, the dense adhesions did not permit us to expose the full length of the graft safely for removal, and as a result, we decided to preserve the graft and lavaged the abscess cavity with povidone-iodine for a month. Combined with long-term antibiotic cover according to antibiotic sensitivity, this strategy has proven to work in this case. The use of well vascularised tissue wrap, such as muscle or omentum around the infected graft, has also been previously reported in literature for treating graft infection.<sup>(9)</sup>

When such conservative approach is taken, the patient should be put on long-term antibiotics according to bacteriological sensitivity, and the duration of therapy should be tailored according to a combination of clinical and haematological parameters. In our case, the patient was put on amoxicillin and clavulanic acid orally for four months until inflammatory markers have normalised and the CT scan confirmed resolution of the infection. The patient is currently on regular tri-monthly reviews at our surgical outpatient clinic with regular blood tests for inflammatory markers. In conclusion, although the conventional management of infected abdominal aortic grafts involve complete graft explantation with *in situ* autologous superficial femoropopliteal vein replacement or extra-anatomical bypass, for patients where the mortality risk for such procedures are extremely high, a conservative approach with surgical drainage combined with cavity lavage

and long-term appropriate antibiotics may at times be successful in eradicating the infection and hence preserving the graft.

## REFERENCES

1. Ting AC, Cheng SW, Ho P, Poon JT, Tsu JH. Surgical treatment of infected aneurysms and pseudoaneurysms of the thoracic and abdominal aorta. *Am J Surg* 2005; 189:150-4.
2. Hsu RB, Tsay YG, Wang SS, Chu SH. Surgical treatment for primary infected aneurysm of the descending thoracic aorta, abdominal aorta, and iliac arteries. *J Vasc Surg* 2002; 36:746-50.
3. Gibbons CP, Ferguson CJ, Edwards K, Roberts DE, Osman H. Use of superficial femoropopliteal vein for suprainguinal arterial reconstruction in the presence of infection. *Br J Surg* 2000; 87:771-6.
4. Nasim A, Hayes P, London N, et al. Vascular surgical society of great britain and ireland: In situ replacement of infected aortic grafts with rifampicin-bonded prostheses. *Br J Surg* 1999; 86:695.
5. Schmitt DD, Seabrook GR, Bandyk DF, Towne JB. Graft excision and extra-anatomic revascularization: the treatment of choice for the septic aortic prosthesis. *J Cardiovasc Surg (Torino)* 1990; 31:327-32.
6. Faulk J, Dattilo JB, Guzman RJ, Naslund TC, Passman MA. Neo-aortic reconstruction for aortic graft infection: need for endovascular adjunctive therapies? *Ann Vasc Surg* 2005; 19:774-81.
7. Pencavel TD, Singh-Ranger G, Crinnion JN. Conservative treatment of an early aortic graft infection due to *Acinetobacter baumannii*. *Ann Vasc Surg* 2006; 20:415-7.
8. Calligaro KD, Veith FJ, Yuan JG, Gargiulo NJ, Dougherty MJ. Intra-abdominal aortic graft infection: complete or partial graft preservation in patients at very high risk. *J Vasc Surg* 2003; 38:1199-205.
9. Takano H, Taniguchi K, Kuki S, et al. Mycotic aneurysm of the infrarenal abdominal aorta infected by *Clostridium septicum*: a case report of surgical management and review of the literature. *J Vasc Surg* 2003; 38:847-51.